Pain Physician 2013; 16:E315-E324 • ISSN 2150-1149

Case Report

Infrapatellar Saphenous Neuralgia – Diagnosis and Treatment

Andrea Trescot, MD[1], Michael N. Brown, MD[2], and Helen W. Karl, MD[3]

From: [1]Algone Pain Center, Wasilla, AK; [2]Monterey Peninsula Orthopedic and Sports Medicine, Monterey, CA; and [3]Department of Anesthesiology and Pain Medicine, University of Washington School of Medicine and Seattle Children's Hospital, Seattle WA.

Dr. Trescot is with the Algone PainCenter, Wasilla AK. Dr. Brown is withthe Monterey Peninsula Orthopedic and Sports Medicine, Monterey, CA. Dr. Karl is Associate Professor of Anesthesiology and Pain Medicine, University of Washington School of Medicine, Seattle Children's Hospital, Seattle, WA.

Address Correspondence:
Andrea Trescot, MD
Algone Pain Center
3066 E. Meridian Park Loop
Wasilla, AK 99654
E-mail: DrTrescot@gmail.com

Disclaimer: There was no external funding in the preparation of this manuscript.
Conflict of interest: None.

Manuscript received: 12-17-2012
Accepted for publication: 01-18-2013

Free full manuscript: www.painphysicianjournal.com

Persistent anterior knee pain, especially after surgery, can be very frustrating for the patient and the clinician. Injury to the infrapatellar branch of the saphenous nerve (IPS) is not uncommon after knee surgeries and trauma, yet the diagnosis and treatment of IPS neuralgia is not usually taught in pain training programs. In this case report, we describe the anatomy of the saphenous nerve and specifically the infrapatellar saphenous nerve branch; we also discuss the types of surgical trauma, the clinical presentation, the diagnostic modalities, the diagnostic injection technique, and the treatment options. As early as 1945, surgeons were cautioned regarding the potential surgical trauma to the IPS. Although many authors dismissed the nerve damage as unavoidable, the IPS is now recognized as a potential cause of persistent anterior and anteriomedial knee pain. Even more concerning, damage to peripheral nerves such as the IPS has been identified as the cause and potential perpetuating factor for conditions such as complex regional pain syndromes (CRPS). Because the clinical presentation may be vague, it has often been misdiagnosed and underdiagnosed. There is a documented vasomotor instability, but, unfortunately, sympathetic blocks will not address the underlying pathology, and therefore patients often will not respond to this modality, although the correct diagnosis can lead to rapid and gratifying resolution of the pathology. An entity unknown to the clinician is never diagnosed, and so it is important to familiarize pain physicians with IPS neuropathy so that they may be able to offer assistance when this painful condition arises.

Key words: infrapatellar saphenous nerve, saphenous neuralgia, nerve injury, knee pain, postoperative pain, peripheral nerve entrapment, diagnostic nerve blocks, complex regional pain syndrome, cryoneuroablation

Pain Physician 2013; 16:E315-E324

Persistent anterior knee pain, especially after surgery, is often a diagnostic enigma. Depending on the procedure or injury, there are many potential causes of this pain. The infrapatellar branch of the saphenous nerve (IPS) (1) is a purely sensory nerve that crosses the inferior knee from medial to lateral and innervates the skin below the patella as well as the anterior inferior knee capsule (2). It may be injured during total knee replacement (TKR) (3-5), patellar (6-9) and hamstring tendon harvest (8-13), open (14-18) and arthroscopic (18-22) repairs, and tibial nailing (23), as well as by anterior knee trauma (24-26). Some patients may have no history of trauma (27,28).

Considering the growing population of elderly

patients and the rise in utilization of total joint arthroplasty (29-31), it will become more commonplace to see IPS neuropathies, neuromas, and neuropathic pain syndromes as a complication of total knee replacements and other procedures involving the knee. Pain management physicians are often unfamiliar with this entrapment neuropathy, and they need to understand the specific symptoms and signs that make IPS injury a likely cause of an individual's anterior knee pain. Anatomical understanding is critical to provide effective selective denervation procedures for IPS neuropathies. The purpose of this case presentation, anatomy review, review of the literature, and description of the diagnostic injections is to familiarize pain physicians with this condition so that clinicians will be able to offer appropriate assistance.

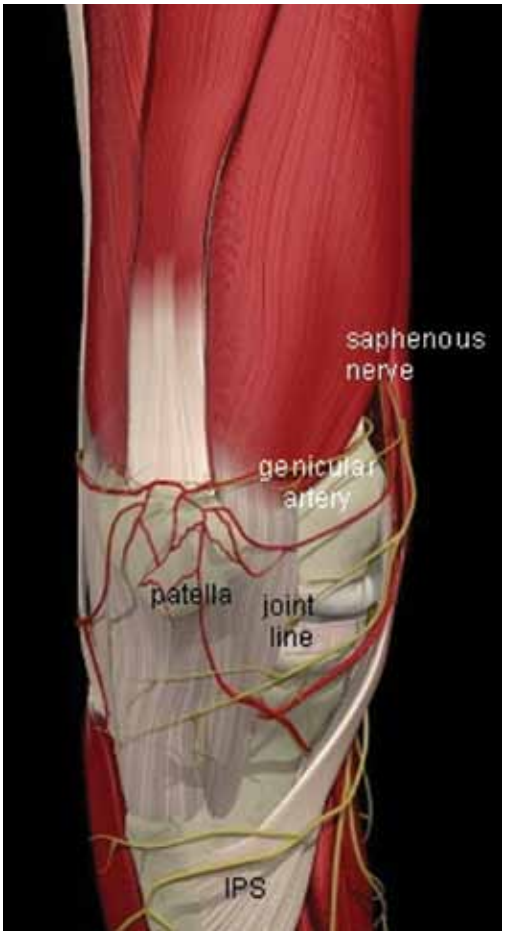

Fig. 1. *The saphenous nerve at the knee (image courtesy of Primalpictures.com, with permission).*

Case Presentation

RB is a 79-year-old man who had persistent knee pain 6 months after TKR. He reported generalized knee pain (medial > lateral) at rest and with movement. Despite aggressive physical therapy, he was unable to flex his knee more than 45 degrees, requiring the use of a wheelchair. On examination, he had diffuse tenderness, allodynia, warmth, swelling, and erythema over the knee. Laboratory studies, including CBC, CRP, and ESR, were normal. He had been diagnosed with complex regional pain syndrome (CRPS Type 1) but had failed a series of lumbar sympathetic blocks at another facility. He was noted to be exquisitely tender to palpation over the medial tibial plateau, consistent with injury of the IPS. An injection of the IPS using 1.5 mL of 0.5% bupivicaine with 40 mg methylprednisolone on the initial visit gave rapid and near-complete pain relief, with resolution of the allodynia, erythema, and swelling. He was able to walk without difficulty within a few minutes. When the pain returned several days later, he underwent cryoneuroablation of the IPS. He made subsequent excellent progress with physical therapy, with sustained good pain relief at his one-year follow-up.

Saphenous Nerve Anatomy

The saphenous nerve, composed of fibers from the L3 and L4 nerve roots, branches from the femoral nerve a few centimeters below the inguinal ligament, then descends through the antero-medial thigh with the femoral artery and vein to the adductor (Hunter's) canal. The femoral vessels travel posteriorly toward the popliteal fossa, while the saphenous nerve and descending genicular branch of the femoral artery penetrate the vastoadductor membrane about 10 cm above the medial femoral epicondyle (Fig.1). At this point, the saphenous nerve is vulnerable to entrapment, resulting in localized tenderness as well as pain in the medial knee radiating to the foot (28,32) (Fig. 2). Depending on their clinical interests, various authors have undertaken cadaver studies and classified the course of the saphenous nerve and its branches in several ways, generally emphasizing its relationship to more constant bony, muscular, and ligamentous structures.

Distal to the vastoadductor membrane, the anatomic variability of the saphenous nerve, and particularly its infrapatellar branch (labeled the infragenicular branch by some) (12) increases. Arthornthurasook was concerned about IPS injury during open knee surgery, so he studied the relationship of the IPS to the sartorius muscle (1). He found that in most (62%) cadaver limbs,

the IPS becomes superficial at the posterior border of the sartorius and crosses the surface of that muscle to the front of the knee. In 22% of his specimens, the nerve penetrated the muscle, in 14% it ran parallel and posterior to the muscle, and in 3% it emerged from the anterior edge of the sartorius. Only half of the knees were identical on both sides.

Mochida and Kikuchi (19) examined IPS anatomy with the perspective of an arthroscopist, focusing on the point at which the IPS crosses the proximal edge of the tibia. They found 2 predominant patterns in the relationship between the patellar ligament and the tibial plateau. More commonly (68%), the IPS crosses the joint line medial to the medial margin of the patellar ligament; in 32% the nerve crosses the patellar ligament proximal to the joint line. Based on his measurement of the distance between the IPS and the medial margin of the patella, they identified a "safe area" for blind puncture to allow passage of an arthroscope. Their findings were soon confirmed by Ebraheim and Mekhail (33). In addition, both Mochida and Kikuchi and Tifford et al (34) observed substantial changes in the position of the IPS depending upon the position of the knee joint.

Kartus et al (7) had a particular interest in bone-patellar tendon-bone (BTB) graft harvest. In a cadaver study, he and his colleagues described the substantial variation in the position of the IPS with respect to the apex of the patella and the tibial tuberosity (35). They also demonstrated differences in the number of branches of the IPS that pass through this region, with 2 branches being the most common (62%).

Horner and Dellon (2), orthopedic and plastic surgeons with an interest in peripheral nerve surgery, documented the location of the division of the IPS branch(es) from the main saphenous nerve trunk (18% proximal thigh, 59% mid-thigh, 24% distal thigh), as well as their relationship to the sartorius muscle and to branches from the femoral and obturator nerves. In most people, 2 or more branches of the saphenous nerve leave the adductor canal proximal to the joint line, the most anterior of which crosses the knee as the IPS to innervate the skin below the patella and the anterior inferior knee capsule. The most posterior branch continues distally as the saphenous (sartorial) nerve (Fig.3).

Arthornthurasook and Gaew-Im (35) followed up the study of the IPS with a detailed examination of the terminal (sartorial) branch of the saphenous nerve. Pagnani and colleagues (36) also focused on this anatomy because of their interest in semitendinosus and gracilis tendon autograft harvest. Both groups found that the

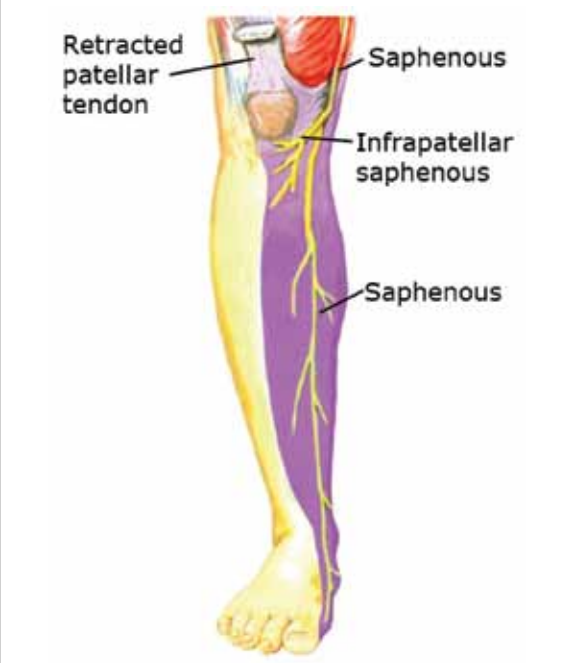

Fig. 2. *The anatomy and pattern of pain of the saphenous nerve at the knee (image modified from Netter by author 2).*

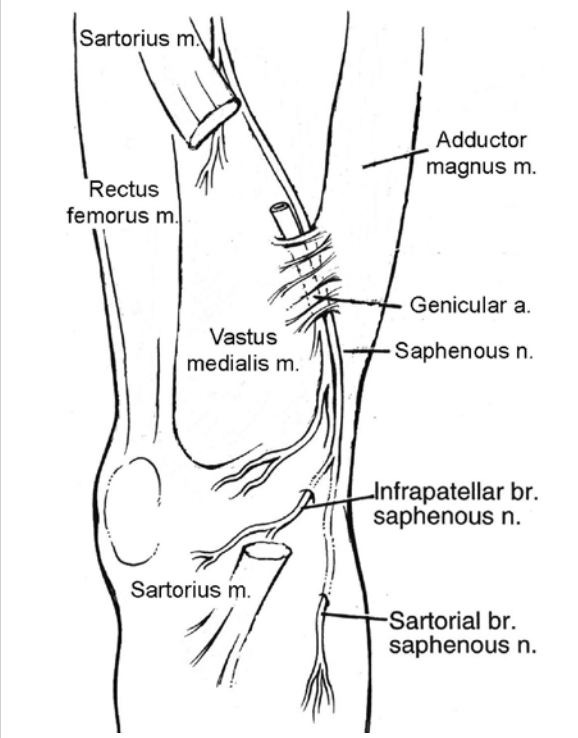

Fig. 3. *The superficial anatomy of the medial knee (modified from Kim by author 1) (58).*

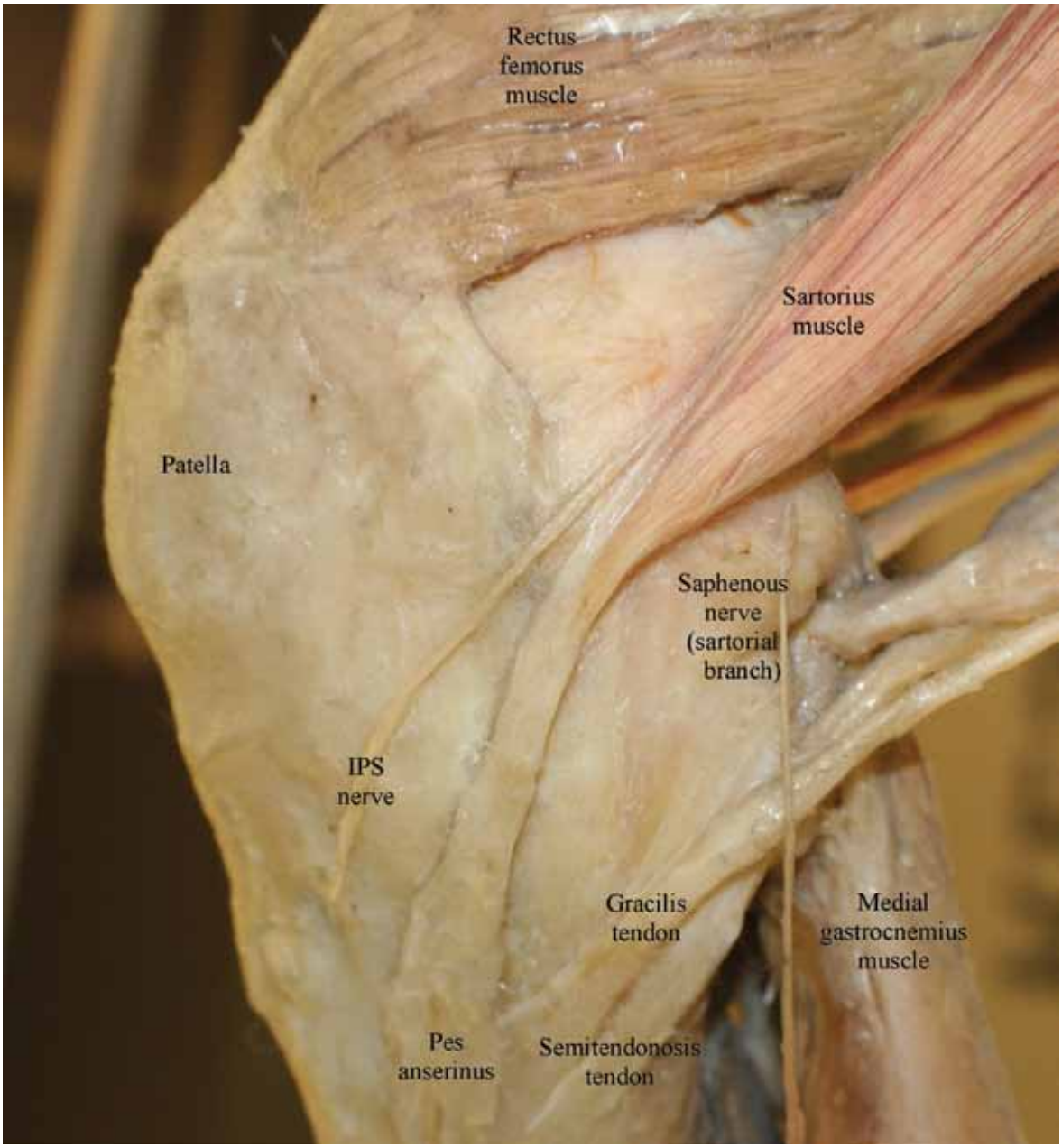

Fig. 4. *The saphenous nerve at the knee (dissection courtesy of Bodies: The Exhibition, with permission).*

sartorial nerve reliably crosses the gracilis tendon at the posteromedial joint line, then becomes more superficial between that tendon and the sartorius muscle (Fig. 4). From there, it continues subcutaneously to supply sensation to the medial leg and foot (35,37,38) As it becomes more superficial, the terminal branch of the saphenous nerve is at risk for injury during hamstring tendon graft harvest and other procedures on the postero-medial knee (20,36,38-41).

These and other authors also emphasize the importance of the medial femoral cutaneous nerve (also called the medial cutaneous nerve of the thigh) (42), a terminal cutaneous branch of the femoral nerve which usually travels superficial to the sartorius muscle and

crosses the knee at the level of the patella to innervate its overlying skin (2). The medial retinacular nerve, the terminal branch of the nerve to the vastus medialis, provides additional innervation to the medial knee; it usually travels in the substance of the muscle, and enters the joint capsule to innervate medial articular structures (2), sending a branch to the medial patella as well (43).

In short, the saphenous nerve and all its major branches are at risk of injury when a surgical procedure or injury involves the medial aspect of the knee. Its high degree of anatomic variability makes the IPS particularly vulnerable.

Surgical Considerations

In their 1945 review "Surgical Approaches to the Knee Joint," Abbott and Carpenter clearly warned of the importance of identification and protection of cutaneous nerves, including the IPS (14). Twenty years later, Huckell (44) provided evidence that numbness and tenderness of the anterior knee were still common after arthrotomy, a fact which "points to the need for care in preserving [the IPS]". This advice was variably followed (19), with some authors considering its destruction inevitable and largely inconsequential (15,17,45). As additional studies and reports identified damage to the IPS as a complication of knee surgery (16), a variety of strategies, such as transillumination (21,22,46) ultrasonography (47), blunt dissection (40), avoidance of tourniquet use (48), graft harvest with the knee in 90° flexion (34), or identification of safe areas with cadaver studies (19,33) have been developed to try to avoid its injury. As we have seen, the course of the IPS is quite variable and injuries will occur despite optimum technique.

The incidence of IPS injury varies with the type of knee surgery, the incision used, and the outcome measure employed. (Table 1).

Clearly, there are many potential causes of pain associated with each kind of knee procedure, so a multidisciplinary team of clinicians must undertake the evaluation of a postoperative patient with anterior knee pain. Involvement of pain management physicians should occur early in the process so as to minimize the duration and extent of disability.

Table 1. *Incidence of IPS Injury*

Author	Date	Surgical Procedure	Incision(s)	Outcome Measure	Time Postop	Result	Comment	Done
Ganzoni	1978	Medial arthrotomy	Medial parapatellar, nerve disregarded (ND) v protected (NP)	Sensory disturbance diagram	2m - 6y	ND: 100% overall (17/17); with 53 % (9/17) "notably disturbed", especially with kneeling. NP: 53% (9/17) partial or complete sensory loss		Y
Hunter	1979	Medial arthrotomy	Medial parapatellar, nerve routinely sectioned	Pt questionnaire	Various	89% overall (67/75); with 63 % (47/75) reporting nonincapacitating irritation, especially kneeling, and 6.7% (5/75) unable to kneel		
Huckell	1965	Open meniscectomy	Various	Pt questionnaire and exam	11-21y	40% (28/70)some kind of neurological abnormality; 31% (22/70) difficulty kneeling	"One of the most distressing problems encountered was the hypesthesia or hyperesthesia which resulted from injury to the IPS..."	Y
Jameson	2007	Arthroscopic ACL: H	Horizontal parapatellar	Pt questionnaire	≥ 13m	IPS: 5% (4/87) SS: 17% (15/87) altered sensation; patients with IPS injury had more activity restriction than SS injury		Y
Johnson, RJ	1974	Open medial meniscectomy	Various	Pt questionnaire and exam	5-37y	24% (18/76) altered sensation, no problem; 21% (16/76) irritation when kneeling; 9% (7/76) unable to kneel		Y

IPS, Infrapatellar branch saphenous nerve; SS, Sartorial branch saphenous nerve; ACL, anterior cruciate ligament repair; H, hamstring autograft; BTB, bone-patellar tendon bone autograft; TKA, total knee arthroplasty

Table 1 (cont.). *Incidence of IPS Injury*

Author	Date	Surgical Procedure	Incision(s)	Outcome Measure	Time Postop	Result	Comment	Done
Johnson, DF	2000	TKA	Medial parapatellar	Outline dermal hypoesthesia	3m-2y	100% (35/35) Size not presence waned over time. No patient reported it to be a significant problem		Y
Leliveld	2012	Tibial nailing	Vertical	Light touch and pain examination	84 ± 37m	60% (43/72) sensory deficit. 61% (44/72) pain when kneeling. 38% (27/72) chronic anterior knee pain, of which 78% also had IPS sensory deficit.	"Incidence of iatrogenic damage to the IPS after tibial nailing is high and lasting. Injury to this N appears to be associated with AKP after tibial nailing."	Y
Liden	2007	Arthroscopic ACL: H v. BTB	H: 30mm oblique BTB: 25 mm (2) vertical	Touch and pain examination	7y	BTB 35%(12/34) H 18%(7/37):Knee walking difficult/impossible (n.s.)	RCT; contrary to findings in shorter-term studies	Y
Mistry	2005	TKA		Light touch and pain examination	6-20m	100% (20/20) some sensory deficit at 1y; 70% by 18m. 10% reported change in sensation significant to dissatisfaction		Y
Mochida	1995	Arthroscopy	8 mm (2) in "safe area"	Light touch and pain examination		22% hypoesthesia (18/81), 1% entrapment (1/81), 2% CRPS (2/81)		Y
Mochizuki	2004	Arthroscopic ACL: H	Vertical	Light touch examination	12-68m	55% overall (47/86) ≥ 1 year post op; 92% Hypoesthesia; recognized by 43%, affected ADL (kneeling) in 1.6% (1/60)		Y
Papastergiou	2006	Arthroscopic ACL: H	Vertical v. horizontal for graft harvest	Touch examination	1-12 m	H: 15% (17/114) V: 40% (46/116) had sensory change P < 0.001		Y
Portland	2005	Arthroscopic ACL: BTB	Vertical v. horizontal for graft harvest	Sensory change pt. questionnaire	≥ 3 yr	H: 43% (18/42) paresthesia V: 59% 20/34) paresthesia at anterolateral knee, taken as evidence of IPS damage		Y
Sanders	2007	Arthroscopic ACL: H	Mini-incisions	Sensory change pt. questionnaire	Various	74% (46/62) sensory change in IPS and/or SS. 6.5% (3/62) affected ADL; none of these had isolated SS damage	Careful anatomic descriptions	Y
Sgaglione	1990	Open ACL: H	Medial parapatellar	Personal interview	24-81m	38% (27/72) IPS numbness; 1.4% (1/72) "significantly bothersome"		Y

IPS, Infrapatellar branch saphenous nerve; SS, Sartorial branch saphenous nerve; ACL, anterior cruciate ligament repair; H, hamstring autograft; BTB, bone-patellar tendon bone autograft; TKA, total knee arthroplasty

Assessment and Diagnosis of IPS Neuropathy

The pattern of pain does not usually help the clinician, since the pain is usually not well localized. The patient describes generalized spontaneous anterior knee pain, perhaps more medially, possibly referred to the medial calf. They may walk "stiff legged" to avoid flexion of the knee. The joint may be red, hot, and swollen, as though infected, with allodynia and pain on movement. Laboratory measurement of inflammatory markers, however, will usually be normal. Especially postoperatively, patients may present with sharp burning pain, hyperesthesia, and/or allodynia that may mimic complex regional pain syndrome (CRPS). There

may be visible swelling in the medial tibial fossa, and palpation of this area usually replicates the pain.

Dellon et al (49) concluded that most patients referred with a diagnosis of CRPS I [no specific nerve injury] actually have continuing pain input from injured joints or chronic cutaneous nerve compression, which is indistinguishable from CRPS II [identifiable single nerve injury], and amenable to successful treatment by means of an appropriate peripheral nerve therapy. Therefore, IPS lesions may be the nidus of a nociceptive barrage that stimulates the neuropathic pain and the subsequent central sensitization, and therefore early diagnosis and specific treatment is key to a positive outcome.

Identification Techniques

Palpation

With the patient seated and the knee flexed, palpation is done with the thumb of the examining hand, placed first on the patellar tuberosity and then moved medially and slightly inferiorly into the medial tibial fossa in an attempt to replicate the pain (Fig. 5). Percussion over the nerve may elicit a paresthesia (Tinel's sign), an additional diagnostic finding.

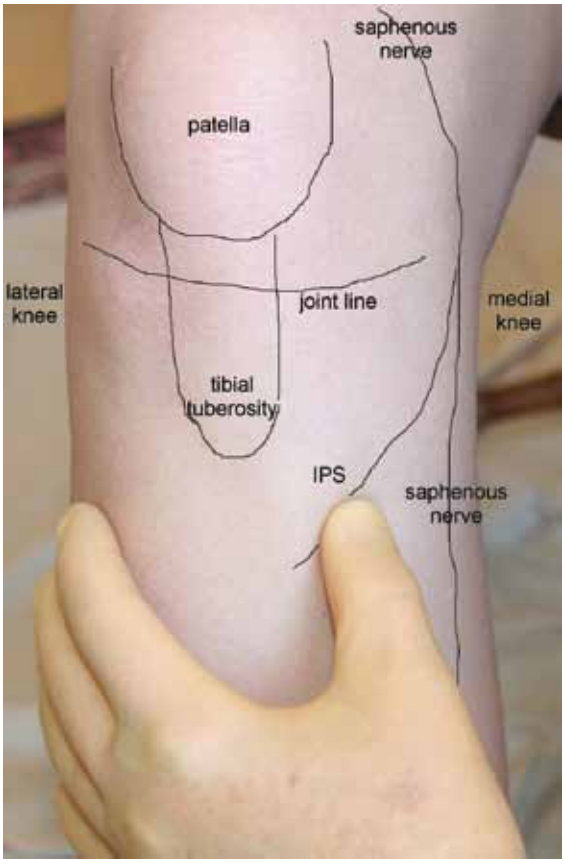

Fig. 5. *Surface landmarks of the IPS .*

Von Frey filament Testing

Von Frey filaments can be used to quantify mechanical allodynia in the cutaneous distribution of the IPS, comparing sensation thresholds of the patient's involved side to their normal side (50). Pressure applied by the filament should be just sufficient to bend the filament on the surface of the skin (Fig. 6).

Nerve Conduction Studies

Sensory nerve conduction studies of the IPS have been described (51), although we have not found this test to be any more useful than a diagnostic IPS injection. Stimulation is performed 2 cm below the patella. The response is recorded with a needle electrode located close to the femoral nerve 2 cm lateral to the femoral artery in the inguinal region. When the IPS was blocked with local anesthetic, the sensory nerve action potential (SNAP) of the IPS but not the main saphenous nerve disappeared, confirming the specificity of the testing site.

Differential Diagnosis

Pathology involving a variety of structures of the medial knee can present with similar signs and symptoms; this includes degenerative X-ray changes, which do not reflect the degree of pain perceived by patients. Distal sartorious tendonitis, pes anserinus bursitis, medial collateral ligament pathology, and medial joint line pathology will all cause medial knee pain. However, patients with IPS neuralgia often are unable to localize pain specifically to the medial knee, the pain is characteristically neuropathic (burning, tingling, allodynia), and the patients are exquisitely tender over the medial tibial fossa.

Diagnostic Injection

With the knee flexed, the non-injecting hand is used to identify and isolate the point of maximum tenderness, with the index and middle fingers straddling the nerve from below (Fig. 7). The needle enters the skin from below, directed toward the tibial tubercle and advanced to bone. Fluoroscopy is not helpful in identifying the nerve, but a peripheral nerve stimulator and/or ultrasound may be useful (47,52). One to 1.5mL of local anesthetic (usually 0.5% bupivicaine) mixed

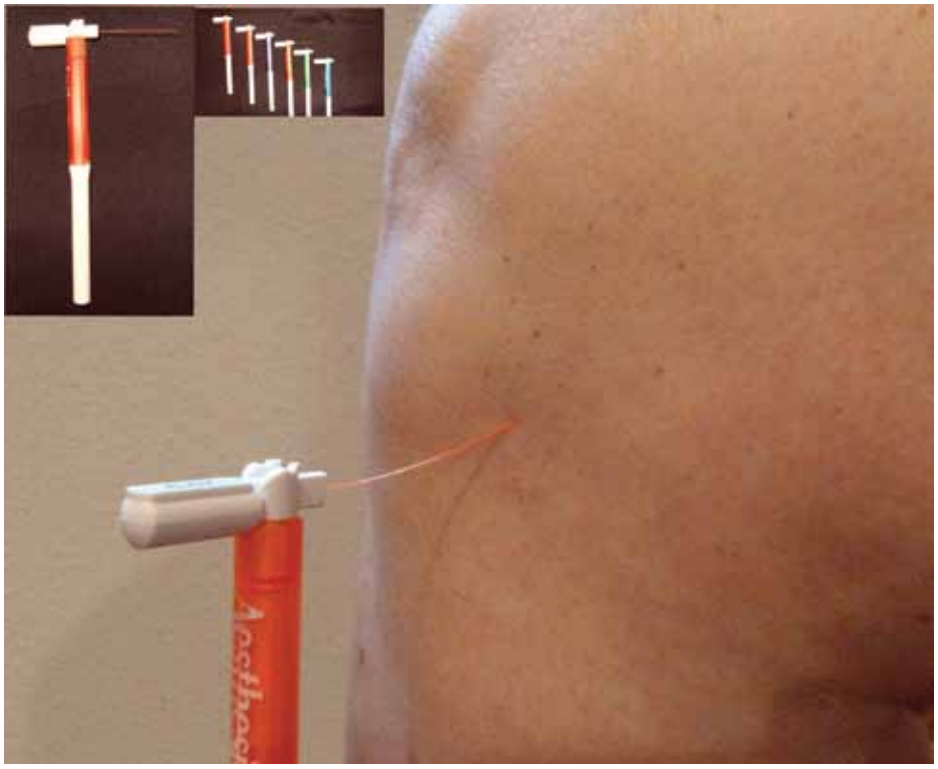

Fig. 6. *Von Frey filaments.*

Fig. 7. *The injection technique for the IPS.*

with a deposteroid (usually methylprednisolone 20 - 40mg) is then injected slowly.

The diagnostic injection technique used to confirm the diagnosis of IPS neuropathy/neuralgia requires that a low volume of injectate be used. Infiltrating large volumes of local anesthetic that spread throughout the anterior proximal tibial tissues will confound the diagnosis. Careful post injection assessment of the degree of symptomatic relief should demonstrate significant improvement in order to confirm the diagnosis.

Subsequent Treatment

The diagnostic injections described above may be therapeutic as well. However, if the injection gives only temporary comfort, there are several options available for longer-term relief. Surgical excision for IPS lesions has been previously described with good success (4,26,53,54). Pulsed radiofrequency has also been described (55). However, we propose that freezing the nerve via cryoneuroablation may be a better option for these patients, because of its simplicity and the lack of subsequent neuroma formation (56). The probe is placed percutaneously, and directed to the nerve using the built-in nerve stimulator. The cryoneuroablation

lesion does not destroy the myelin sheath of a nerve, thereby providing a channel for nerve regeneration and recovery. The prolonged relief from one or 2 cryoneuroablation procedures often halts the nociceptive stimulus long enough for the patient to recover from the accompanying central sensitization (57).

Potential Complications

The most likely complication of the diagnostic/therapeutic injection is skin atrophy due to the steroid injected. This is avoided by depositing the injectate as deep in the tissues as possible.

Conclusion

Despite advances in orthopedic surgical technique, injury to the IPS continues to be a cause of post-operative anterior knee pain, but may occur after any anterior knee trauma or even spontaneously. Pain physicians should familiarize themselves with the pathophysiology, anatomy, diagnosis, and treatment of IPS pain syndromes. By doing so, they can save patients from unnecessary pain and suffering and provide a valuable service to an orthopedic colleague who has had a patient with this unfortunate outcome. Early recognition and aggressive treatment should greatly decrease the suffering and disability that occurs when the proper diagnosis has not been made. The diagnostic injections are often therapeutic, providing long-term relief. Cryoneuroablation may be the most desirable treatment for persistent pain; the results can be quite gratifying and repeated treatment is usually not required.

References

1. Arthornthurasook A, Gaew-Im K. Study of the infrapatellar nerve. *Am J Sports Med* 1988; 16:57-59.
2. Horner G, Dellon AL. Innervation of the human knee joint and implications for surgery. *Clin Orthop Relat Res* 1994; 301:221-226.
3. Dellon AL, Mont MA, Krackow KA, Hungerford DS. Partial denervation for persistent neuroma pain after total knee arthroplasty. *Clin Orthop Relat Res* 1995; 316:145-150.
4. Johnson DF, Love DTT, Love BRT, Lester DK. Dermal hypoesthesia after total knee arthroplasty *Am J Ortho* 2000; 29:863-866.
5. Toms AD, Mandalia V, Haigh R, Hopwood B. The management of patients with painful total knee replacement. *J Bone Joint Surg B* 2009; 91:143-150.
6. Beaufils P, Gaudot F, Drain O, Boisrenoult P, Pujol N. Mini-invasive technique for bone patellar tendon bone harvesting: Its superiority in reducing anterior knee pain following ACL reconstruction. *Curr Rev Musculoskelet Med* 2011; 4:45-51.
7. Kartus J, Movin T, Karlsson J. Donor-site morbidity and anterior knee problems after anterior cruciate ligament reconstruction using autografts. *Arthroscopy* 2001; 17:971-980.
8. Plancher KD, Steadman JR, Briggs KK, Hutton KS. Reconstruction of the anterior cruciate ligament in patients who are at least forty years old. A long-term follow-up and outcome study. *J Bone Joint Surg Am* 1998; 80:184-197.
9. Shaieb MD, Kan DM, Chang SK, Marumoto JM, Richardson AB. A prospective randomized comparison of patellar tendon versus semitendinosus and gracilis tendon autografts for anterior cruciate ligament reconstruction. *Am J Sports Med* 2002; 30:214-220.
10. Papastergiou SG, Voulgaropoulos H, Mikalef P, Ziogas E, Pappis G, Giannakopoulos I. Injuries to the infrapatellar branch(es) of the saphenous nerve in anterior cruciate ligament reconstruction with four-strand hamstring tendon autograft: Vertical versus horizontal incision for harvest. *Knee Surg Sports Traumatol Arthrosc* 2006; 14:789-793.
11. Wittstein JR, Wilson JB, Moorman CT. Complications related to hamstring tendon harvest. *Oper Tech Sports Med* 2006; 14:15-19.
12. Spicer DDM, Blagg SE, Unwin AJ, Allum RL. Anterior knee symptoms after four-strand hamstring tendon anterior cruciate ligament reconstruction. *Knee Surg Sports Traumatol Arthrosc* 2000; 8:286-289.
13. Figueroa D, Calvo R, Vaisman A, Campero M, Moraga C. Injury to the infrapatellar branch of the saphenous nerve in ACL reconstruction with the hamstrings technique: Clinical and electrophysiological study. *Knee* 2008; 15:360-363.
14. Abbott LC, Carpenter WF. Surgical approaches to the knee joint. *J Bone Joint Surg* 1945; 27:277-310.
15. Chambers GH. The prepatellar nerve: A cause of suboptimal results in knee arthrotomy. *Clin Orthop Relat Res* 1972; 82:157-159.
16. Hunter LY, Louis DS, Ricciardi JR, O'Connor GA. The saphenous nerve: Its course and importance in medial arthrotomy. *Am J Sports Med* 1979; 7:227-230.
17. Swanson AJG. Incidence of prepatellar neuropathy following medial meniscectomy. *Clin Orthop Relat Res* 1983; 181:151-153.
18. Mintzer CM, Richmond JC, Taylor J. Meniscal repair in the young athlete. *Am J Sports Med* 1998; 26:630-633.
19. Mochida H, Kikuchi S. Injury to infrapatellar branch of saphenous nerve in arthroscopic knee surgery. *Clin Orthop Relat Res* Nov 1995; 320:88-94.
20. Bertram C, Porsch M, Hackenbroch MH, Terhaag D. Saphenous neuralgia after arthroscopically assisted anterior cruciate ligament reconstruction with a semitendinosus and gracilis tendon graft. *Arthroscopy* 2000; 16:763-766.
21. Sherman OR, Fox JM, Snyder SJ, Del Pizzo W, Friedman M, Ferkel, R, Lawley M. Arthroscopy--"no-problem surgery." An analysis of complications in two thousand six hundred and forty cases. *J Bone Joint Surg Am* 1986; 68:256-265.
22. Poehling GG, Pollock Jr FE, Koman LA. Reflex sympathetic dystrophy of the knee after sensory nerve injury. *Arthroscopy* 1988; 4:31-35.
23. Leliveld MS, Verhofstad MHJ. Injury to the infrapatellar branch of the saphe-

nous nerve, a possible cause for anterior knee pain after tibial nailing? *Injury* 2012; 43:779-783.
24. Detenbeck LC. Infrapatellar traumatic neuroma resulting from dashboard injury. *J Bone Joint Surg Am* 1972; 54:170-172.
25. Lippitt AB. Neuropathy of the saphenous nerve as a cause of knee pain. *Bull Hosp Jt Dis* 1993; 52:31-33.
26. Tennent TD, Birch NC, Holmes MJ, Birch R, Goddard NJ. Knee pain and the infrapatellar branch of the saphenous nerve. *J R Soc Med* 1998; 91:573-575.
27. House JH, Ahmed K. Entrapment neuropathy of the infrapatellar branch of the saphenous nerve. *Am J Sports Med* 1977; 5:217-224.
28. Kopell HP, Thompson WAL. Knee pain due to saphenous nerve entrapment. *N Engl J Med* 1960; 263:351-353.
29. Leskinen J, Eskelinen A, Huhtala H, Paavolainen P, Remes V. The incidence of knee arthroplasty for primary osteoarthritis grows rapidly among baby boomers: A population-based study in Finland. *Arthritis Rheum* 2012; 64:423-428.
30. Kurtz S, Ong K, Lau E, Mowat F, Halpern M. Projections of primary and revision hip and knee arthroplasty in the United States from 2005 to 2030. *J Bone Joint Surg Am* 2007; 89:780-785.
31. Jain NB, Higgins LD, Ozumba D, Guller U, Cronin M, Pietrobon R, Katz J. Trends in epidemiology of knee arthroplasty in the United States, 1990–2000. *Arthritis Rheum* 2005; 52:3928-3933.
32. Romanoff ME, Cory PC, Kalenak A, Keyser GC, Marshall WK. Saphenous nerve entrapment at the adductor canal. *Am J Sports Med* 1989; 17:478-481.
33. Ebraheim NA, Mekhail AO. The infrapatellar branch of the saphenous nerve: An anatomic study. *J Orthop Trauma* 1997; 11:195-199.
34. Tifford CD, Spero L, Luke T, Plancher KD. The relationship of the infrapatellar branches of the saphenous nerve to arthroscopy portals and incisions for anterior cruciate ligament surgery: An anatomic study. *Am J Sports Med* 2000; 28:562-567.
35. Kartus J, Ejerhed L, Eriksson BI, Karlsson J. The localization of the infrapatellar nerves in the anterior knee region with special emphasis on central third patellar tendon harvest: a dissection study on cadaver and amputated specimens. *Arthroscopy* 1999; 15:577-586.36. Pagnani MJ, Warner JJ, O'Brien SJ, Warren RF. Anatomic considerations in harvesting the semitendinosus and gracilis tendons and a technique of harvest *Am J Sports Med* 1993; 21:565–571.
37. Dunaway DJ, Steensen RN, Wiand W, Dopirak RM. The sartorial branch of the saphenous nerve: Its anatomy at the joint line of the knee. *Arthroscopy* 2005; 21:547-551.
38. Sanders B, Rolf R, McClelland W, Xerogeanes J. Prevalence of saphenous nerve Injury after autogenous hamstring harvest: An anatomic and clinical study of sartorial branch injury. *Arthroscopy* 2007; 23:956-963.
39. Solman CG, Pagnani M. Hamstring tendon harvesting. Reviewing anatomic relationships and avoiding pitfalls. *Orthop Clin North Am* 2003; 34:1-8.
40. Mochizuki T, Muneta T, Yagishita K, Shinomiya K, Sekiya I. Skin sensory change after arthroscopically-assisted anterior cruciate ligament reconstruction using medial hamstring tendons with a vertical incision. *Knee Surg Sports Traumatol Arthrosc* 2004; 12:198-202.
41. Jameson S, Emmerson K. Altered sensation over the lower leg following hamstring graft anterior cruciate ligament reconstruction with transverse femoral fixation. *Knee* 2007; 14:314-320.
42. Dellon AL. Partial denervation for the treatment of painful neuromas complicating total knee replacement. In: Scott WN (ed). *Insall & Scott: Surgery of the Knee.* 5th ed. Elsevier Churchill Livingstone, Philadephia, 2012.
43. Maralcan G, Kuru I, Issi S, Esmer AF, Tekdemir I, Evcik D. The innervation of patella: Anatomical and clinical study. *Surg Radiol Anat* 2005; 27:331-335.
44. Huckell JR. Is meniscectomy a benign procedure? A long-term follow-up study. *Can J Surg* 1965; 8:254-260.
45. Larson RL. Editorial comment. *Am J Sports Med* 1979; 7:230.
46. Kelly M, MacNicol MF. Identification of the saphenous nerve at arthroscopy. *Arthroscopy* 2003; 19:E46.
47. Le Corroller T, Lagier A, Pirro N, Champsaur P. Anatomical study of the infrapatellar branch of the saphenous nerve using ultrasonography. *Muscle Nerve* 2011; 44:50-54.
48. DeLee JC. Complications of arthroscopy and arthroscopic surgery: Results of a national survey. *Arthroscopy* 1985; 1:214-220.
49. Dellon L, Andonian E, Rosson GD. Lower extremity complex regional pain syndrome: Long-term outcome after surgical treatment of peripheral pain generators. *J Foot Ankle Surg* 2010; 49:33-36.
50. Landerholm ÅH, Hansson PT. The perception threshold counterpart to dynamic and static mechanical allodynia assessed using von Frey filaments in peripheral neuropathic pain patients. *Scand J Pain* 2011; 2:9-16.
51. Bademkiran F, Obay B, Aydogdu I, Ertekin C. Sensory conduction study of the infrapatellar branch of the saphenous nerve. *Muscle Nerve* 2007; 35:224-227.
52. Lundblad M, Kapral S, Marhofer P, Lönnqvist P-A. Ultrasound-guided infrapatellar nerve block in human volunteers: Description of a novel technique. *Br J Anaesth* 2006; 97:710-714.
53. Nahabedian MY, Johnson CA. Operative management of neuromatous knee pain: Patient selection and outcome. *Ann Plast Surg* 2001; 46:15-22.
54. Mistry D, O'Meeghan C. Fate of the infrapatellar branch of the saphenous nerve post total knee arthroplasty. *ANZ J Surg* 2005; 75:822-824.
55. Akbas M, Luleci N, Dere K, Luleci E, Ozdemir U, Toman H. Efficacy of pulsed radiofrequency treatment on the saphenous nerve in patients with chronic knee pain. *J Back Musculoskelet Rehabil* 2011; 24:77-82.
56. Trescot A. Cryoanalgesia in interventional pain management. *Pain Physician* 2003; 6:345-360.
57. Moesker AA, Karl HW, Trescot AM. Treatment of phantom limb pain by cryoneurolysis of the amputated nerve. *Pain Practice* 2012; Dec 19. doi: 10.1111/papr.12020. [Epub ahead of print]